

Tonsillar Lymphangiomatous Polyp – Report of Two Cases –

Han Suk Ryu • Soo Young Jung
Jae-Soo Koh • Seung-Sook Lee

Department of Pathology, Korea Cancer
Center Hospital, Korea Institute of
Radiological and Medical Sciences,
Seoul, Korea

Received : June 12, 2006
Accepted : August 18, 2006

Corresponding Author

Seung-Sook Lee, M.D.
Department of Pathology, Korea Cancer Center
Hospital, Korea Institute of Radiological and Medical
Sciences, 215-4 Gongneung-dong, Nowon-gu, Seoul
139-706, Korea
Tel: 02-970-2545
Fax: 02-970-2430
E-mail: sslee@kcch.re.kr

Tonsillar lymphangiomatous polyp is an uncommon hamartomatous lesion that generally arises from the tonsillar surface, and it has rarely been reported in the medical literature. Because of the uncommon clinical and pathological features of these polyps, pathologists and clinicians may experience difficulty in correctly classifying them. We report herein two cases of lymphangiomatous polyp of the tonsil in a 49 year-old man and a 30 year-old man who both presented with a tonsillar mass of the palatine tonsil. Microscopically, there were protruding polypoid lesions that had a core of fibroadipose tissue with dilated multiple lymphatics and aggregated lymphoid tissue. Both patients have been stable since resection.

Key Words : Tonsil; Lymphangioma; Polyp; Hamartoma

Tonsillar lymphangiomatous polyp is a kind of hamartomatous lesion and it has been described by different nomenclatures such as lymphangiectatic fibrous polyp, polypoid lymphangioma of the tonsil, hamartomatous tonsillar polyp and so on.^{1-4,6,8} It is lined by squamous epithelia and its stroma is composed of variably loose or more dense collagenous tissue and adipose tissue, and this usually contains dilated lymphatic channels and various components of lymphoid tissue.¹

It is a rare polypoid mass that generally arises from a pedicle attached to the tonsil and projecting into the oropharynx.² Although this is a rare clinical and pathologic entity for pathologists and clinicians, the diagnosis is not so difficult if one has a bit of experience about that. Therefore, we present here our experience on two cases of lymphangiomatous polyp of the tonsil.

CASE REPORT

Case 1

A 49-year-old man was admitted to the Korea Cancer Center

Hospital with polypoid oral cavity mass, which had been present for one month. He complained of foreign body sensation, however he was otherwise asymptomatic. He was not a smoker and was healthy with no previous surgery or treatment. The physical examination revealed a pedunculated tumor extending from the right palatine tonsil. There was no evidence of cervical lymphadenopathy. The patient underwent a right tonsillectomy. Grossly, a 1.1 × 0.4 cm sized polypoid mass was found to be attached to the tonsil with a slender stalk; it was firm and fibrotic. The cut surface was smooth and white to tan (Fig. 1).

Histologically, it was lined by squamous epithelium, and its stroma was composed of fibrous and adipose tissue, numerous dilated lymphatic channels and aggregates of lymphoid tissue (Fig. 2). At 16 months of follow-up period, the patient remained well.

Case 2

A 30-year-old man presented with a painful mass in his oral cavity, and this mass had been present for one week. However a round to ovoid mass was first noted 10 years ago. He was not a smoker, and he had undergone appendectomy 2 years ago. The

physical examination revealed a firm protruding mass from the left tonsillar surface.

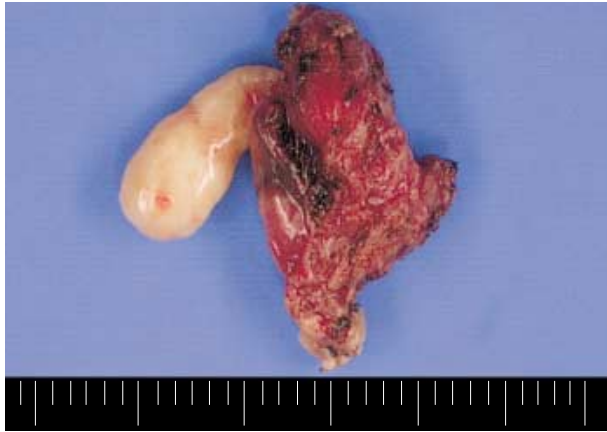

Fig. 1. Gross photograph of right tonsillectomy specimen. A Polypoid mass extends from tonsil, showing smooth surface. [left: polyp, right: tonsil] (case 1).

Left tonsillectomy was performed. Grossly, the mass measured 0.9×0.8 cm, and it was well demarcated. It was attached to the outer surface of the tonsil without stalk. The cut surface was gray to tan and partly fibrotic.

Histologically, the mass showed an almost hyalinized fibrotic stroma with a focal edematous area and aggregation of lymphocytes. The mass was covered by benign squamous epithelium. Any prominent proliferation of lymphatic channels were not identified (Fig. 3A, B). Masson trichrome staining and Congo-red staining revealed no amyloid deposition, but there was fibrotic change in the hyalinized stroma (Fig. 3C, D). The post-operative course has been uneventful for 7 months of follow up.

DISCUSSION

Benign tumors or tumor-like lesions of the palatine tonsil are

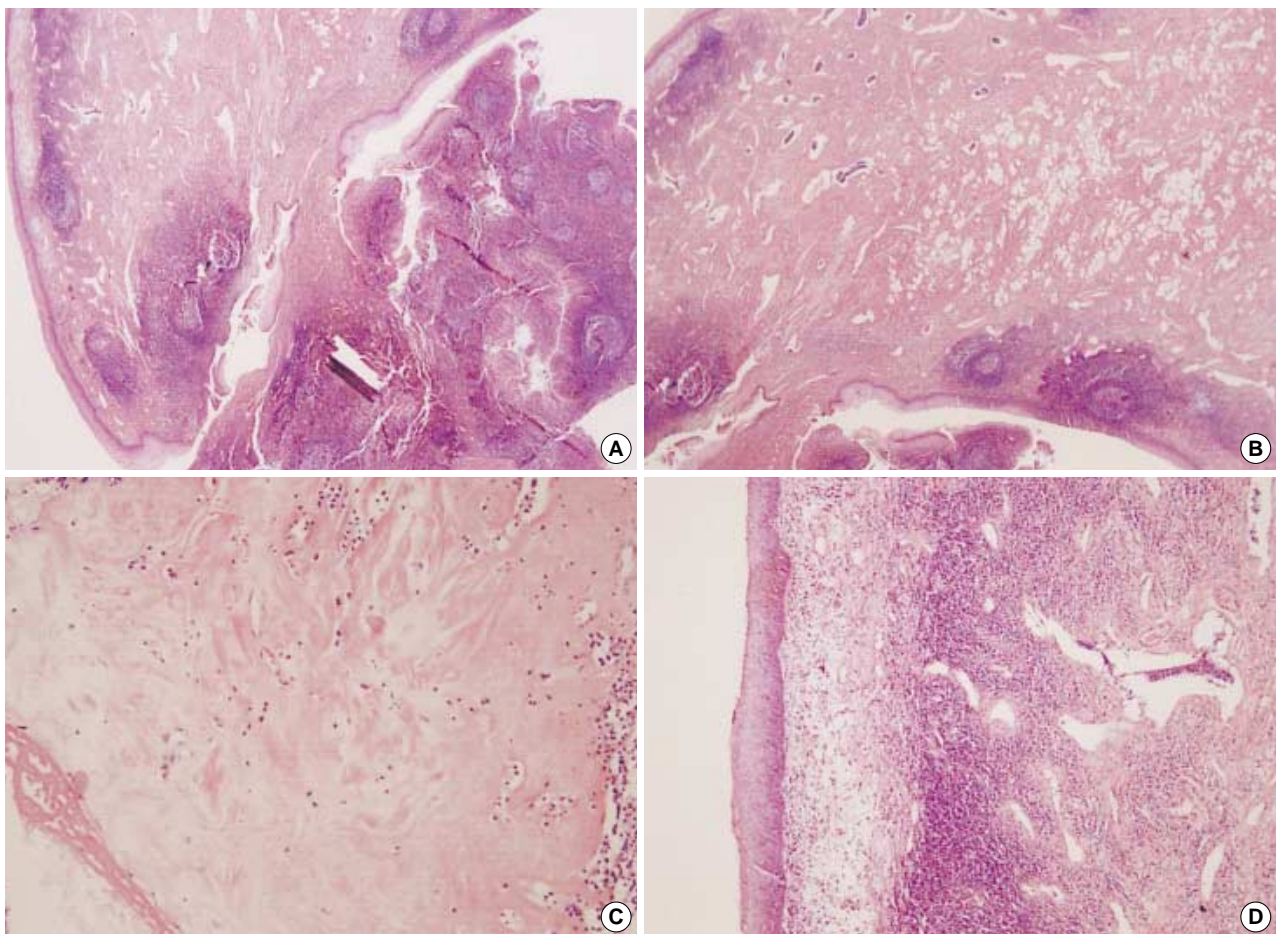


Fig. 2. Histology of the case no. 1. (A) The polyp arises from tonsil. [left upper: polyp, right lower: tonsil]. Proliferation of lymphatic channel in stroma is noted. (B) The stroma is composed of fibrous and adipose tissues containing aggregates of lymphoid tissue with lymphoid follicle formation. (C) Hyalinization in stroma is partly seen. (D) surface is lined by squamous epithelium.

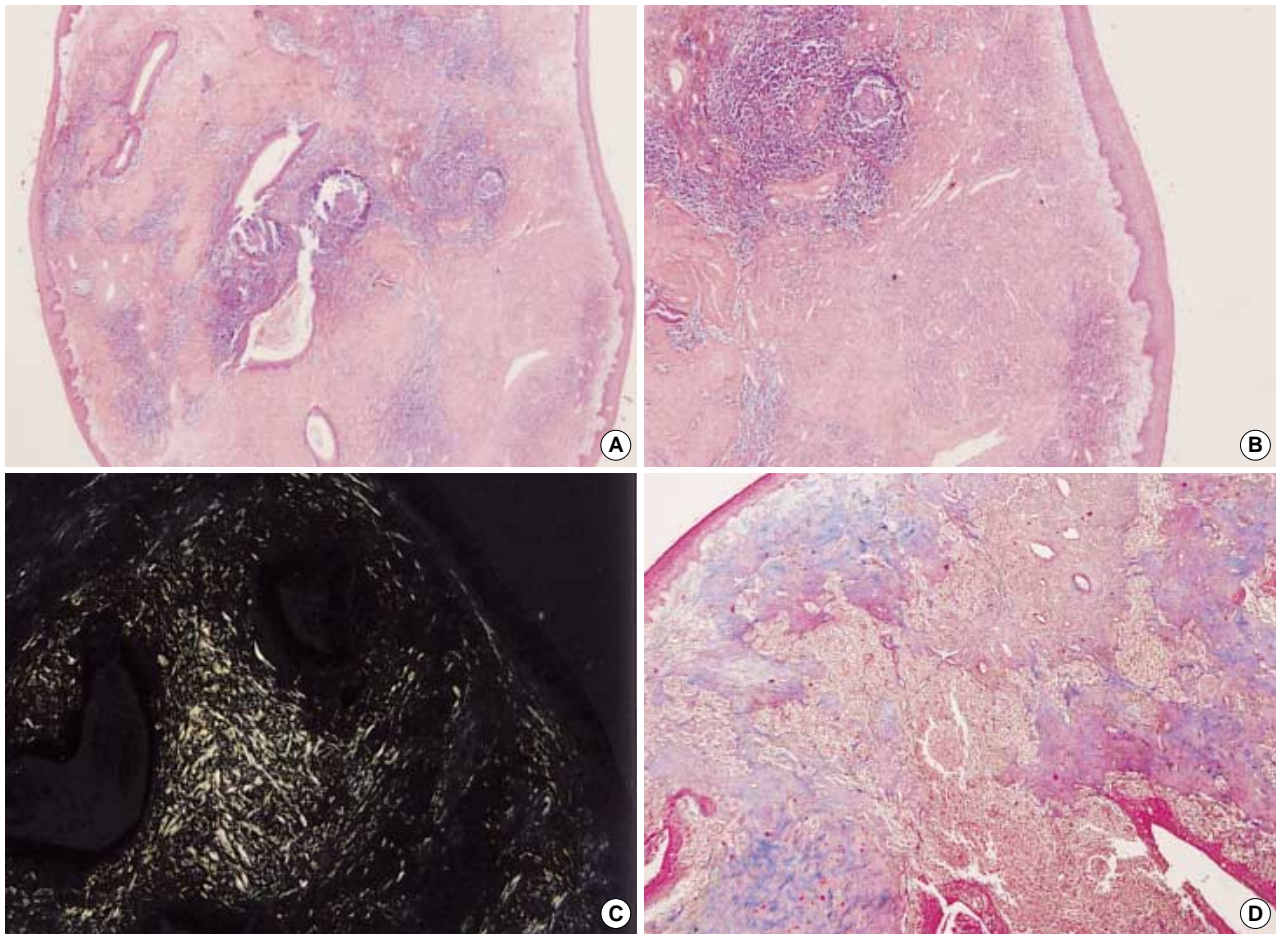


Fig. 3. Histology of the case no. 2. (A) The polyp shows round to ovoid growth appearance. (B) The mass is covered by benign squamous epithelium. Stroma is almost hyalinized fibrotic and focally edematous with aggregation of lymphocytes. Focal proliferation of lymphatic space is identified. (C) Congo-red staining with polarizing microscope shows no amyloid deposition in the hyalinized stroma. (D) Masson trichrome staining shows fibrotic change of hyalinized stroma.

less common than malignant ones. Squamous papilloma accounts for the majority of the benign lesions, whereas vascular tumors are rarely reported.³ The tonsil is a less common site for the development of lymphangiomatous lesions. Kardon *et al.*⁶ reviewed 26 cases of lymphangiomatous polyps and they described the various histologic features of the polyps. They were usually covered by squamous epithelium and showed a variable degree of epithelial hyperplasia and proliferation of lympho-vascular channels. Collagen, adipose tissue and lymphocytic infiltration were present in the stroma.⁶ The immunoprofiles of these lesions in a large series revealed dilated lymphatic vessels, which contained at least a thin wall of smooth muscle, and they were uniformly reactive for the factor VIII-related antigens, CD31 and CD34.⁶ Nevertheless, immunohistochemistry is not needed for definitive diagnosis.⁶

Up to the present, pathologists have had difficulty in specifically classifying their cases, and they have named them as fibro-

lipomas or have given them a more descriptive diagnosis, such as "polypoid tumor containing fibroadipose tissue."⁴

In this report, the second case showed a prominent fibrous stroma, compared with lymphangiomatous proliferation. Because of the stromal paucicellularity and hyalinization, Congo-red staining was performed for making the differential diagnosis from amyloidosis: negative Congo-red staining and positive Masson trichrome staining generally reveal fibrous lymphangiomatous polyps that usually have a relatively paucicellular fibrous background in this case. Therefore, some authors have found it difficult to diagnose and precisely classify this as lymphangiomatous polyp that contains mainly fibroadipose tissue.⁵ Heffner *et al.* also reviewed the pathology of lymphangiomatous polyps that displayed a wide spectrum of histological features, including varying amounts of fibrous and lymphoid tissues.² Kardon *et al.*⁶ agreed which the fact that fibroadipose stromal components are more frequently abundant than lymphatic channels. For this

reason, the true incidence of these lesions is difficult to accurately assess from the literature, which shows the range from 1.9% of all tonsillar tumors⁶ to 8% of all benign tonsillar tumors.⁷

Some authors maintain the assertion that these lesions are most likely hamartomatous, because of a haphazard proliferation of stromal elements that are normally found in the tonsil.⁸ Our cases of lymphangiomatous polyp contained dense fibrous connective tissue, rich lymphocyte infiltration, and adipocytes with varying amounts of lympho-vascular proliferation. These components in our cases were the normal constituents of this site, except for the fact that they were arranged in a different pattern. Therefore, they are most likely to represent a hamartomatous proliferation rather than a typical lymphangioma.

The differential diagnoses should include juvenile angiofibroma, papilloma, and lymphangioma. It is important to distinguish lymphangiomatous polyps from juvenile angiofibroma, since the latter lesion should usually be treated more aggressively to prevent possible recurrence. Clinically, angiofibromas typically occur in the nasopharynx of adolescent males, often as large tumors with extensive growth and even bone erosion and present with epistaxis due to the rich blood supply. Histologically, the stroma of angiofibromas is more cellular, composed of stellate and plump cells, and contains branching thin walled vascular channels. On the other hand, lymphangiomatous polyps usually have a relatively paucicellular fibrous background and more lymphocytes, and squamous papilloma is usually an exophytic surface epithelial proliferation that is arranged in multiple layers lacking lymphatic and lymphocytic components. When lymphangiomas are described, they usually contain widely dilated vascular chan-

nels with luminal proteinaceous fluid and lymphocytes.

Lymphangiomatous polyps of the tonsil are rare benign hamartomatous lesions that present as masses and they can be cured by simple surgical excision. After surgical excision, there has been no incidence of recurrence or malignant transformation reported in the medical literature .

REFERENCES

1. Hiraide F, Inouye T, Tanaka E. Lymphangiectatic fibrous polyp of the palatine tonsil. A report of three cases. *J Laryngol Otol* 1985; 99: 403-9.
2. Heffner DK. Pathology of the tonsils and adenoids. *Otolaryngol Clin North Am* 1987; 20: 279-86.
3. Roth M. Lymphangiomatous polyp of the palatine tonsil. *Otolaryngol Head Neck Surg* 1996; 115: 172-3.
4. Al Samarrae SM, Amr SS, Hyams VJ. Polypoid lymphangioma of the tonsil: report of two cases and review of the literature. *J Laryngol Otol* 1985; 99: 819-23.
5. Lake CF, Zimmerman AL, Parkhill EM. An unusual polypoid tumor of the tonsil. *Ann Otol Rhinol Laryngol* 1962; 71: 1005-8.
6. Kardon DE, Wenig BM, Heffner DK, Thompson LD. Tonsillar lymphangiomatous polyps: a clinicopathologic series of 26 cases. *Mod Pathol* 2000; 13: 1128-33.
7. Hyams VJ. Differential diagnosis of neoplasia of the palatine tonsil. *Clin Otolaryngol Allied Sci* 1978; 3: 117-26.
8. Shara KA, al-Muhana AA, al-Shennawy M. Hamartomatous tonsillar polyp. *J Laryngol Otol* 1991; 105: 1089-90.