



# Iatrogenic Gastric Pseudolipomatosis during Endoscopic Submucosal Dissection

Sang Wook Kim · Woo Sung Moon<sup>1</sup>

Division of Gastroenterology, Department of Internal Medicine and <sup>1</sup>Department of Pathology, Research Institute of Clinical Medicine of Chonbuk National University-Biomedical Research Institute of Chonbuk National University Hospital and Research Institute for Endocrine Sciences, Chonbuk National University Medical School, Jeonju, Korea

Mucosal pseudolipomatosis of the stomach is a rare lesion. It is characterized by the presence of gas-filled vacuoles in the lamina propria.<sup>1</sup> The etiology of this lesion is uncertain. Herein, we present a case of gastric pseudolipomatosis with an unusual iatrogenic artifact while performing injection of submucosal solution during endoscopic submucosal dissection (ESD).

## CASE REPORT

The patient had provided written informed consent for publication of this case study.

A 63-year-old woman was admitted for evaluating gastric submucosal lesion incidentally detected during a health check-up. Upon endoscopic examination, a single smooth surfaced polypoid lesion sized 1 cm was identified. Under the clinical impression of submucosal benign mesenchymal tumor, ESD was performed. Normal saline and indigo carmine dye mixed with hyaluronic acid was injected into the submucosal layer to lift up the lesion and distinguish the muscle layer from the submucosal layer. The endoscopist did not detect any visible mucosal changes before injecting the solution (Fig. 1A). However, the release of air bubbles from the lesion was clearly observed during the submucosal dissection (Fig. 1B). Microscopic examination of the submucosal tumor was consistent with inflammatory fibroid polyp. The lamina propria contained numerous un-

lined empty spaces without inflammatory reaction, measuring 40–600  $\mu\text{m}$  in diameter and extending to the submucosa and submucosal tumor (Fig. 2A, B). Neither specific cytological abnormalities nor architectural destruction was found in the mucosa. *Helicobacter pylori* was not identified. The lesion showed negative immunohistochemical staining results for D2-40, CD31, CD34, vimentin, and S100 protein. Therefore, lymphangiomatic lesion and lipomatous metaplasia were ruled out (Fig. 2C). These histologic findings were similar, if not identical, to those of gastrointestinal pseudolipomatosis reported previously.<sup>1,2</sup> Based on histological and immunohistochemical findings, a final diagnosis of gastric pseudolipomatosis was made.

## DISCUSSION

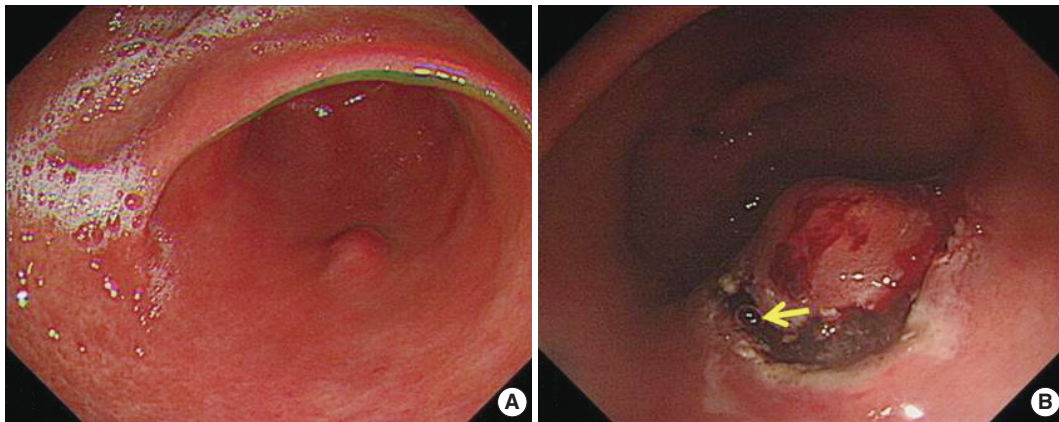
Gastrointestinal pseudolipomatosis is characterized by the presence of gas-filled vacuoles of various sizes within the lamina propria. It is named as gastrointestinal pseudolipomatosis because it resembles fatty infiltration.<sup>1,2</sup> Histologically, differential diagnoses of pseudolipomatosis include lymphangiomatic lesion and lipomatous metaplasia which can be easily excluded by using appropriate immunohistochemical staining. The etiology of pseudolipomatosis is unclear. Penetration of gas into the injured mucosa associated with air pressure during endoscopy,<sup>1</sup> *H. pylori* infection,<sup>3</sup> and the use of disinfectant hydrogen peroxide solution have been proposed as possible etiologies.<sup>4</sup> We propose that our case is an artifact caused by infusion of incompletely removed air inside the syringe caused by inadequate flushing when injecting the submucosal solution (Fig. 2D). Several facts

### Corresponding Author

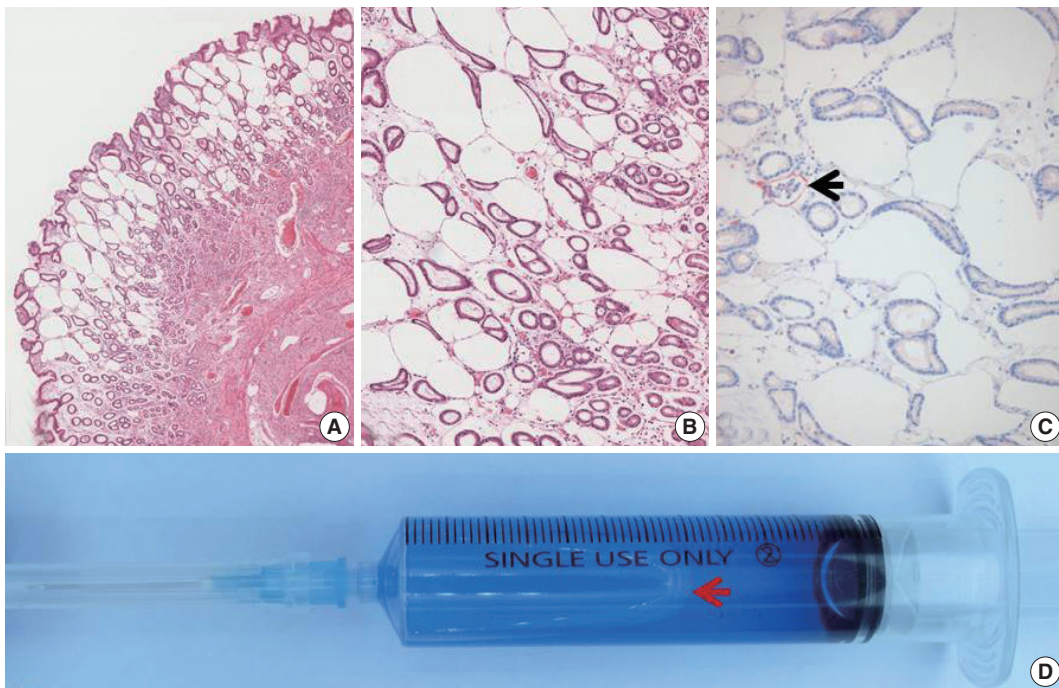
Woo Sung Moon, MD, PhD  
Department of Pathology, Chonbuk National University Medical School, 567 Baekje-daero, Deokjin-gu, Jeonju 54896, Korea  
Tel: +82-63-270-3086, Fax: +82-63-270-3135, E-mail: mws@chonbuk.ac.kr

Received: March 16, 2017 Revised: April 18, 2017

Accepted: April 24, 2017



**Fig. 1.** Endoscopic findings. (A) Endoscopic appearance of a single polypoid lesion without any visible mucosal changes. (B) Appearance of air bubble during submucosal dissection (arrow).



**Fig. 2.** Morphologic findings of the lesion. (A) Submucosal inflammatory fibroid polyp and a number of clear vacuoles overlying within the mucosa, mimicking lymphangioma or lipomatous metaplasia. (B) High resolution view of the lesion. The characteristic appearance of pseudodolipomatosis shows a number of unlined empty spaces with various sizes in an otherwise intact mucosa. (C) Negative immunoreactivity for D2-40 on vacuoles. D2-40 immunostaining highlighted the preexisting lymphatic structures (arrow). (D) Presence of incompletely removed air inside the syringe (arrow).

support this notion. First, there were no apparent etiologic factors in our case. There was no mucosal lesion such as atrophy or ulcer. In addition, *H. pylori* was not identified. Hydrogen peroxide was not used either. Second, there was no inflammatory or fibroblastic reaction in the vicinity of unlined empty spaces, suggesting short duration of this lesion. Third, the endoscopist noted incompletely removed air in the syringe containing submucosal solution and observed air bubbles being released from

the gastric tissue during submucosal dissection. This lesion may represent a gastric pseudolipomatosis with an undescribed unique iatrogenic artifact while performing injection of submucosal solution during ESD procedure. Recognition of this iatrogenic artifact is important to endoscopists and pathologists because it is preventable. In addition, it might mimic other lesions, such as mucosal lymphangioma or lipomatous metaplasia.

---

**Conflicts of Interest**

No potential conflict of interest relevant to this article was reported.

**Acknowledgments**

This work was supported by the National Research Foundation of Korea (NRF) grant funded by the Korean Government (MSIP) (No. 2008-0062279).

**REFERENCES**

1. Stebbing J, Wyatt JL. Gastric 'pseudolipomatosis'. *Histopathology* 1998; 32: 283-4.
2. Snover DC, Sandstad J, Hutton S. Mucosal pseudolipomatosis of the colon. *Am J Clin Pathol* 1985; 84: 575-80.
3. Alper M, Akcan Y, Belenli OK, Cukur S, Aksoy KA, Suna M. Gastric pseudolipomatosis, usual or unusual? Re-evaluation of 909 endoscopic gastric biopsies. *World J Gastroenterol* 2003; 9: 2846-8.
4. Jonas G, Mahoney A, Murray J, Gertler S. Chemical colitis due to endoscope cleaning solutions: a mimic of pseudomembranous colitis. *Gastroenterology* 1988; 95: 1403-8.