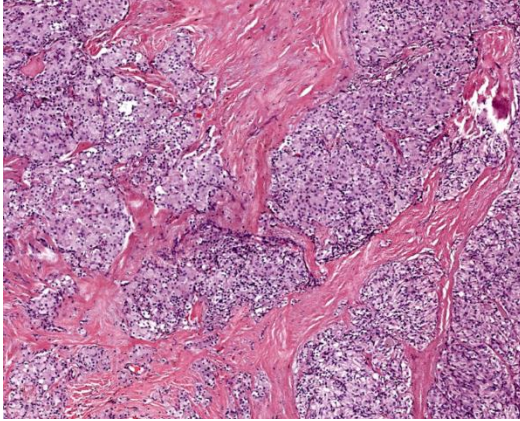
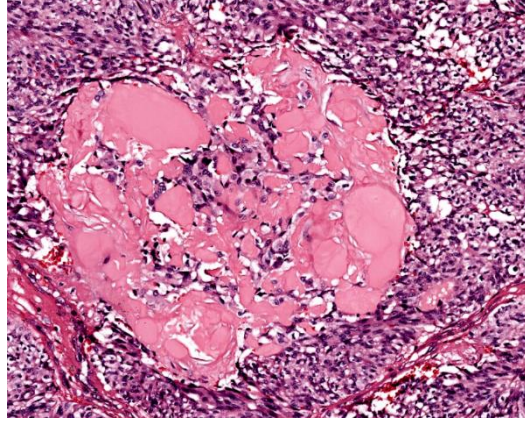
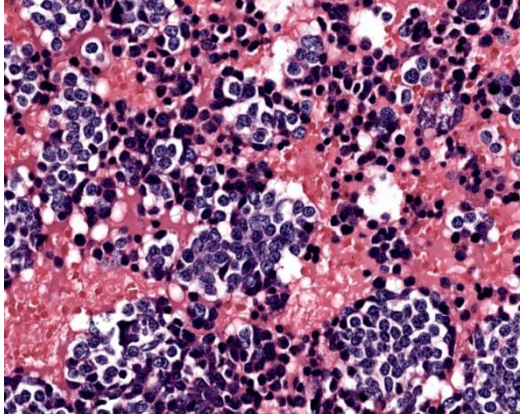
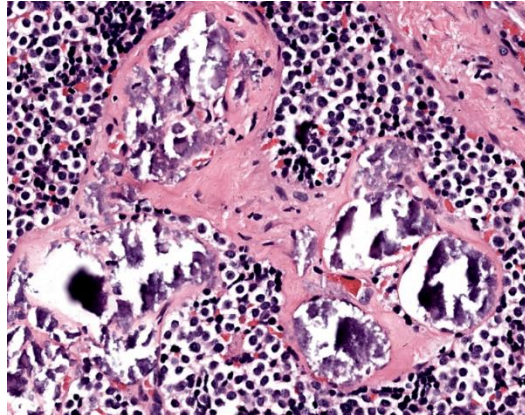


**A****B****C****D**

**Supplementary Fig. S4.** Stromal tissue characteristics: (A) sclerosis, (B) amyloid deposits, (C) hemorrhage, and (D) calcification.