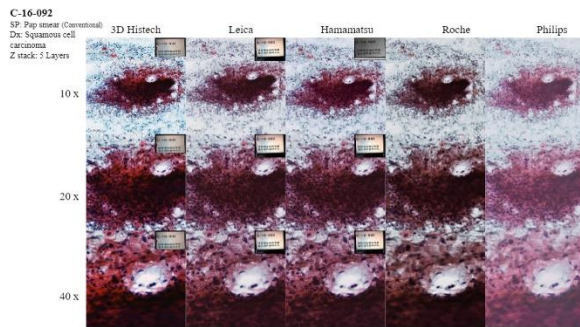
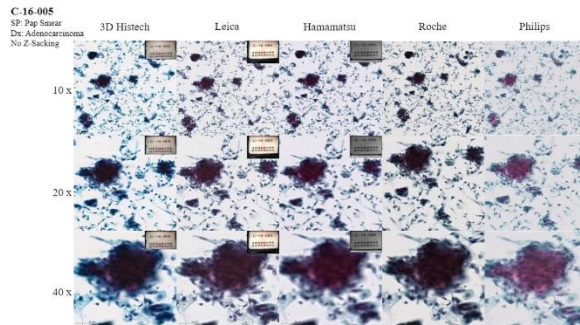



(A)




(B)



(C)



(D)



Supplementary Fig. S2. Difference in scanned images of remaining representative samples. (A) Squamous cell carcinoma on a conventional Pap smear scanned with five layers of z-stacking. (B) Adenocarcinoma on a liquid-based Pap smear scanned without z-stacking. (C) Squamous cell carcinoma of the lungs on a